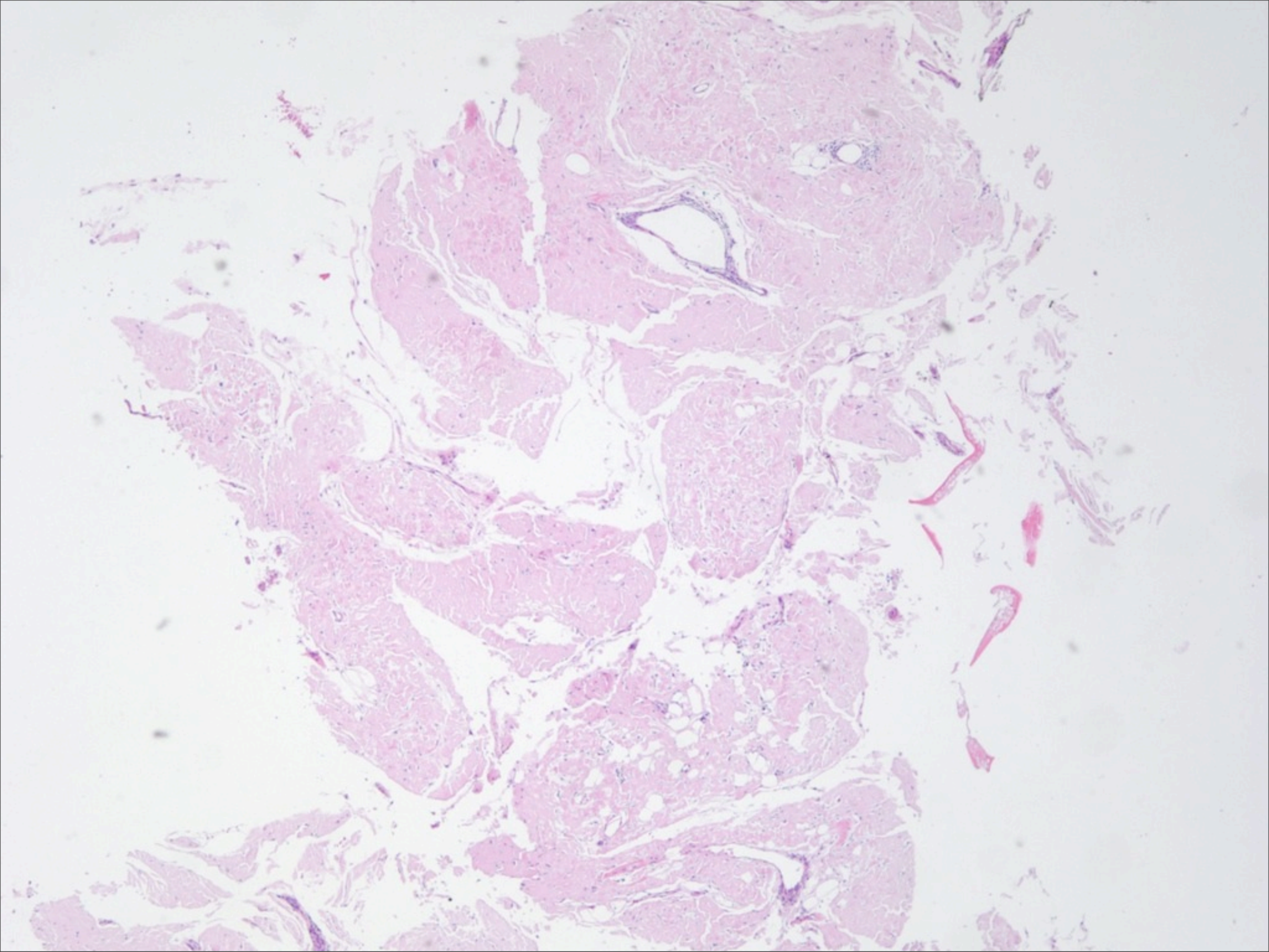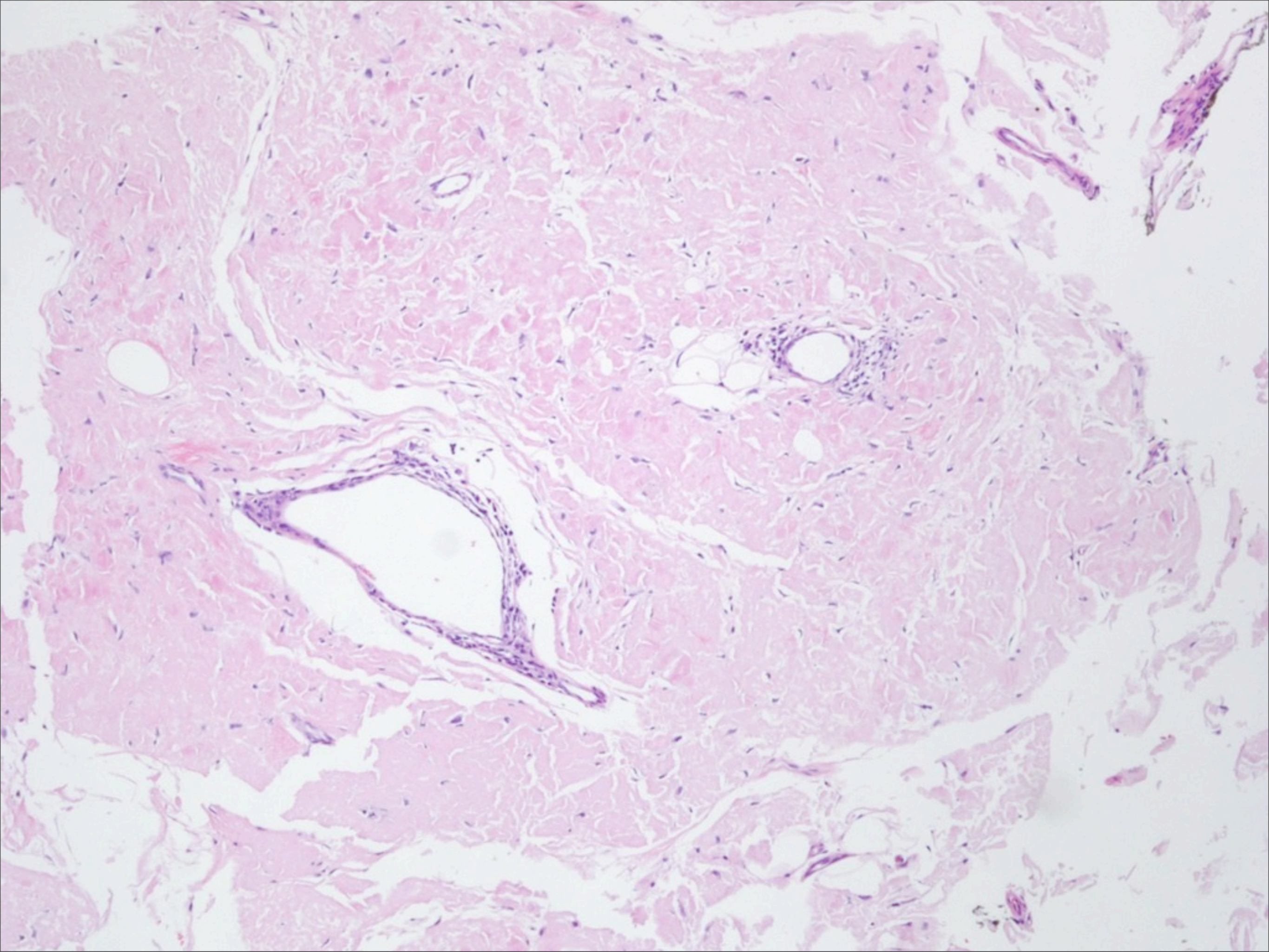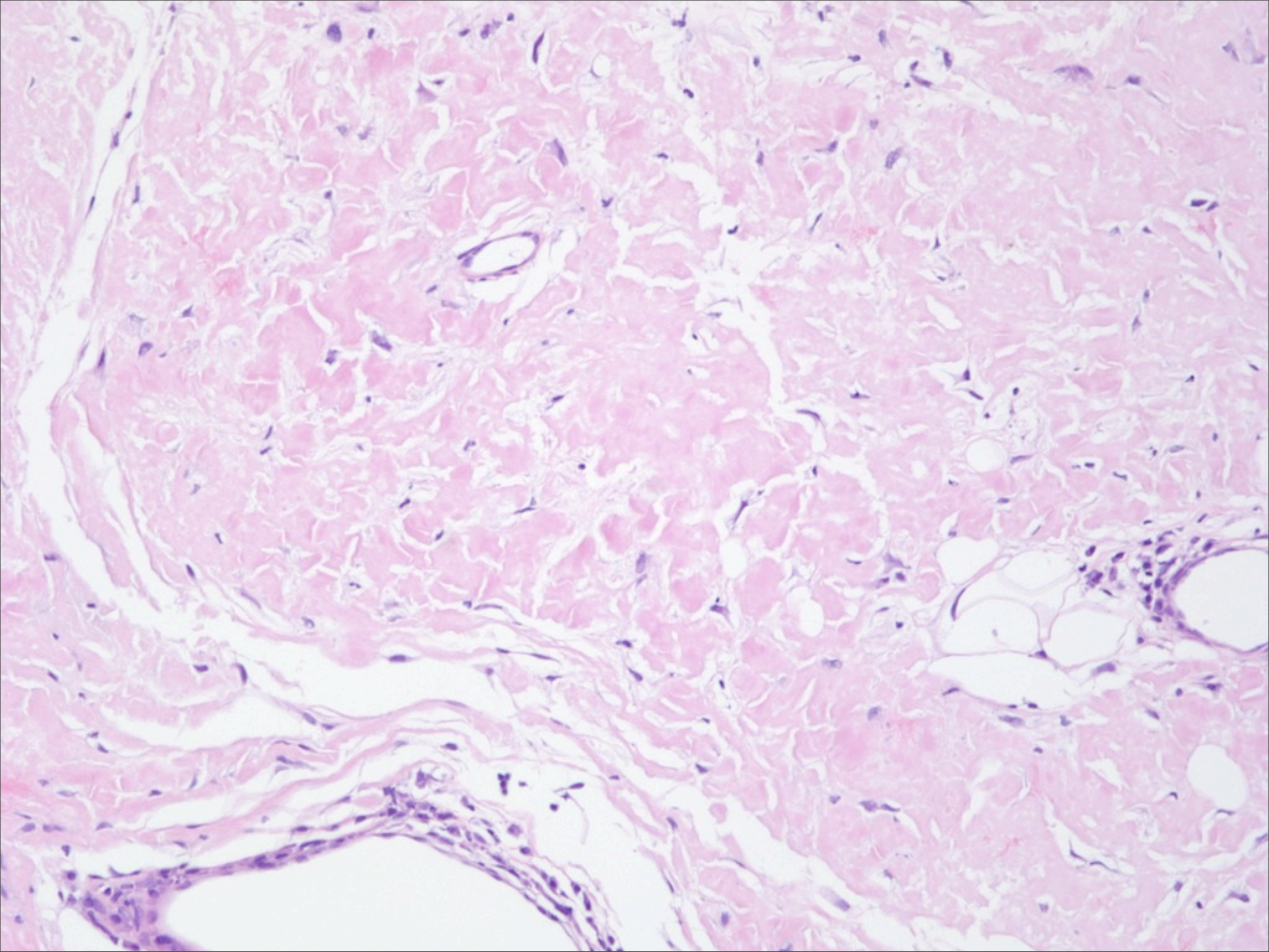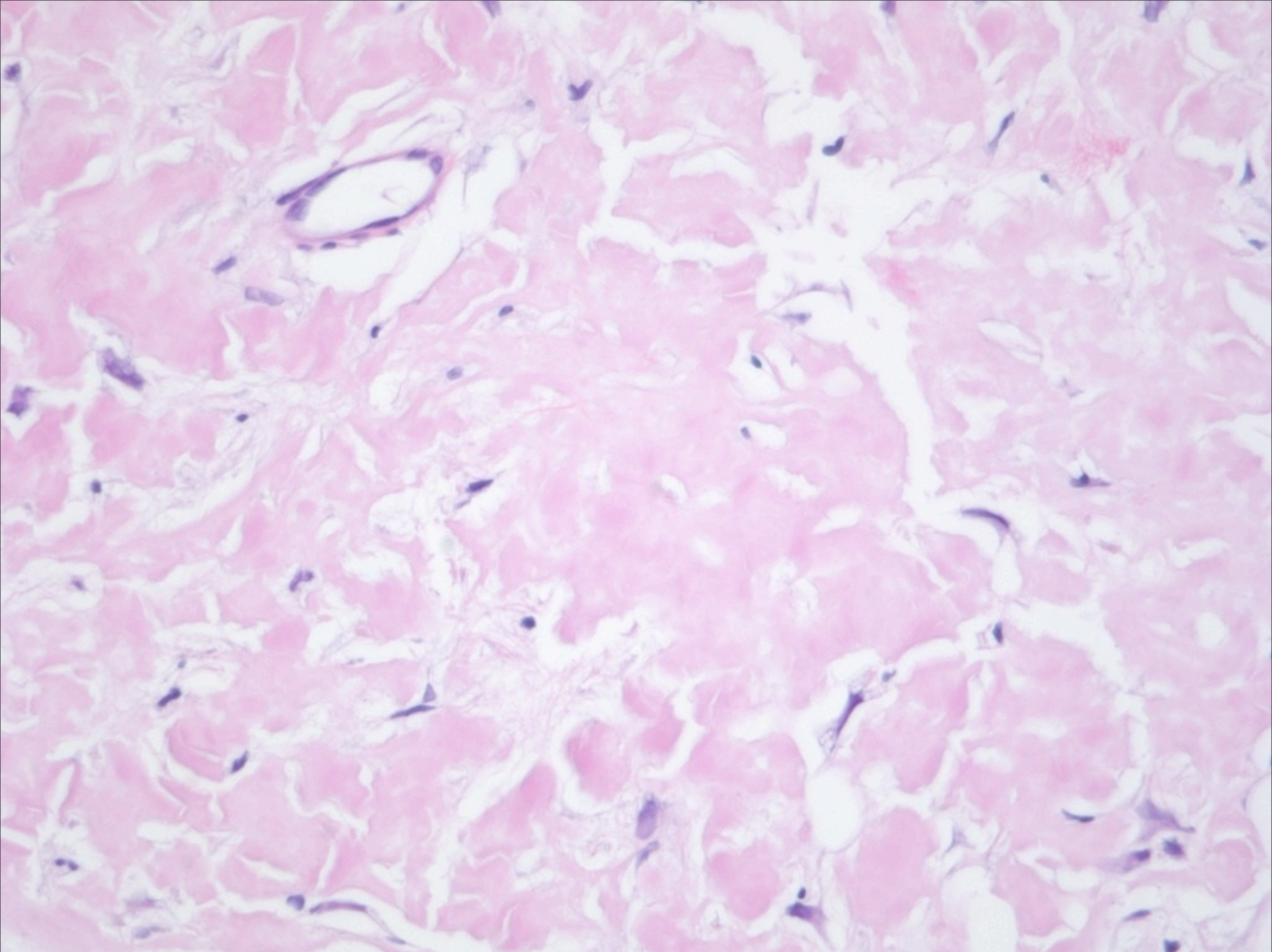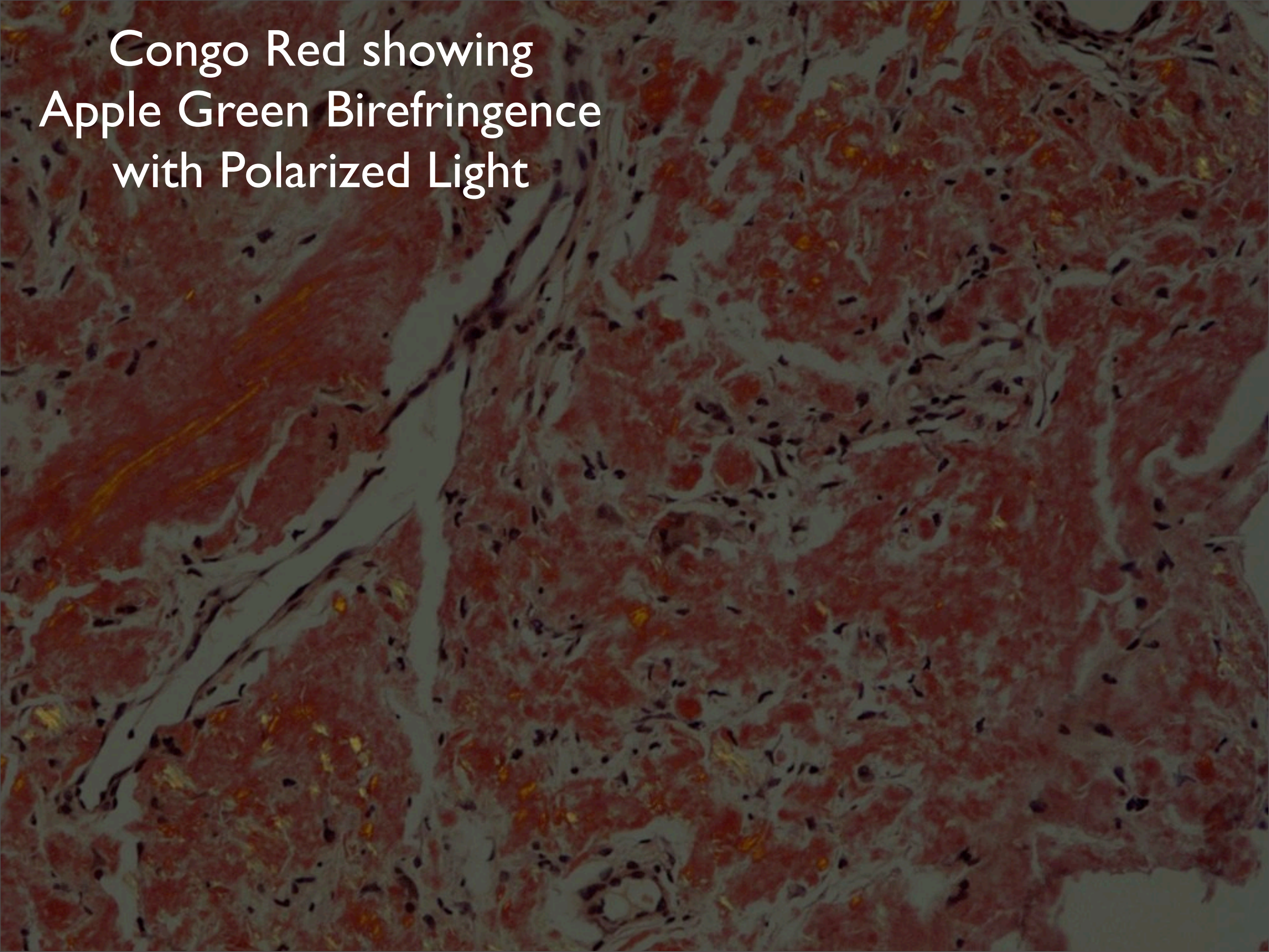


What is the best diagnosis?

- Granulation tissue
- Keloid
- Amyloid
- Cutaneous Mucinosis
- Radiation dermatitis

Amyloidoma

Congo Red showing Apple Green Birefringence with Polarized Light



Hyalinized Dermal and Soft Tissue Deposits

Confirm with Congo Red